



CLINICAL AND HISTOLOGICAL EVALUATION OF THE REGENERA[®] METHOD FOR THE TREATMENT OF ANDROGENETIC ALOPECIA

Xavier Álvarez, MD¹, Miguel Valenzuela, MD¹, Jaume Tuffet, MD¹

¹ Clínica Tuffet. Passeig de Gràcia, 86, 08008 Barcelona.

ABSTRACT

Androgenetic alopecia has become a more common condition in society, affecting both genders. It is a disorder of multifactorial origin, with therapeutic options both in the rise and under development. Known options include the procedures of regenerative medicine with promising results. This paper assesses clinical and histological changes in patients with AGA after applying an autologous cellular suspension obtained using the Rigenera[®] system. After applying treatment, an increase in the mean of hair thickness, together with reduction of its loss, have been objectified; the level of satisfaction described by patients is worth noting. Based on the results, the improvement of AGA obtained with the Rigenera system is objective; these results need to be completed with data from future studies after using this promising technique.

KEYWORDS: Alopecia. Regenerative medicine, AGA, Rigenera.

1. INTRODUCTION:

Both male and female androgenetic alopecia (AGA), also known as common baldness, is the most frequent condition in our society. It is estimated to have affected 80% of Caucasian males and approximately 42% of women in the 90s. [1,2] Both genders share its causes, which are mainly genetic inheritance, hormones and aging of the hair follicle.

Hair follicles are complex structures that go through different biological stages: from an active growth stage (anagen phase) and an intermediate remodeling stage (catagen phase), to a quiescent stage (telogen phase). [2] The pathogenesis of androgenetic alopecia is characterized by a shortening of the anagen phase and an increase in the amount of hair follicles that remain in the telogen phase. Since the anagen phase determines hair's length, the new hair in AGA is shorter, gradually miniaturizing hair follicles until they disappear. [3,4] In male pattern AGA, a receding front line is observed, mainly of triangular shape, followed by thinning at the vertex area. [5] The so-called female pattern is characterized by diffuse thinning of the central-parietal region and preservation of hair front line. [1]

AGA is a disorder of multifactorial origin, in which genetics plays an important role. In males, it is an androgen-dependent feature since the terminal follicle becomes susceptible to Dihydrotestosterone (DHT), shortening the anagen phase; whereas in women, the associated hormonal mechanisms are less evident. [2]

Hair density loss needs follow-up and continued treatment. In this sense, therapeutic options —prescribed or natural—promoting hair growth have recently experienced a great rise, and hair regeneration has become one of the main goals of developing therapies. [5]

The purpose of this paper is to objectively assess changes in the scalp, hair bulbs and hair in a number of patients with AGA, after applying an autologous cellular suspension obtained using the Rigenera[®] system. The treatment involves the administration of intradermal injections in the affected area of one single application of an autologous cellular suspension obtained using the Rigenera[®] system (Human Brain Wave SRL, Turin, distributed in Spain by the Rigenera Activa company) from an autologous skin graft.

2. MATERIALS AND METHODS:

The treatment consists of the mechanical disintegration of a sample of tissue obtained by a skin punch and subsequent filtration (50 microns) to be intradermally administered in the affected area according to technical specifications (Rigenera[®] Protocol, Rigenera[®] System, Human Brain Wave SRL, Turin).

For this descriptive study, 17 patient volunteers were consecutively and randomly recruited. The defined inclusion criteria were: males and females over 18 years old diagnosed with AGA. Of the 17 patients that were treated with the Rigenera[®] system, nine were males aged between 24 and 54. According to the scale of Hamilton, they all showed the following male pattern: three had type III, two had type IV, three had type V, and one had type VI. Of the 17 patients treated, eight were women aged between 21 and 58, with female pattern androgenetic alopecia. According to the Ludwig scale, they were classified as follows: two had type III, and six reported hair loss, although without a diagnosis of AGA.

Exclusion criteria included: allergy to lidocaine, healing issues, scarring alopecia, chronic drug treatment, oncologic processes and having performed any hair loss treatment topical, oral or injectable between 3 months prior and 3 months after the date of applying treatment except taking vitamin supplements and applying topical lotions or shampoos. The application was made on the scalp using mesotherapy. In males, the treatment was applied in areas 2, 3, 4, 5 and 6, while in females, it was applied in all ten areas (fig. 1).

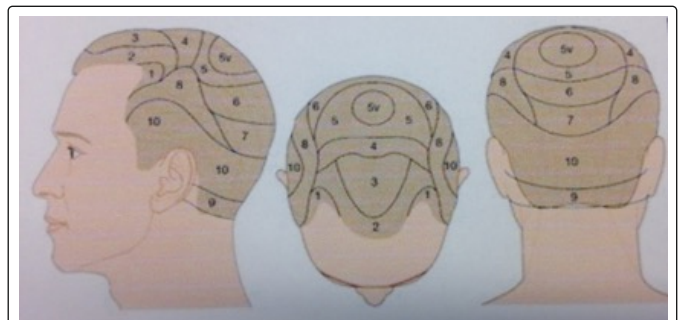


Figure 1: Application areas

Control visits were conducted prior to treatment and 30 days after its application. Eight pictures per session were taken for analysis in a photographic studio. These were assessed by a doctor specialized in hair medicine, who was not part of the study. The variables assessed were:

1. Evidence of improvement: comparison of pictures taken before treatment with those taken 30 days later (Table 1).
2. Assessment of improvement according to scales of Hamilton and Ludwig.

Patients' level of satisfaction with the treatment was recorded as well, along with their perception of changes in hair thickness, density, and loss (table 1). Lastly, immediately after each session, patients recorded the level of pain during application.

3. RESULTS:

The analysis of the photographic evaluation (fig. 2) showed an improvement of hair density in four patients, that is 23.53%. Thirteen patients (76.47%) didn't notice any change, and none of them noticed worsening of hair density.

As for the subjective assessment of satisfaction, of the 17 patients treated, one patient was very satisfied (5.88%), five patients were quite satisfied (29.41%), eight patients were satisfied (47.05%), one patient was somewhat satisfied (5.88%) and two were unsatisfied (11.76%).

Concerning patients' perception of change in hair thickness, 12 patients observed an increase in thickness (70.58%) and five did not observe any change (29.41%).

Concerning patients' perception of change in hair loss, no increase was observed: nine did not notice any change (52.94%) and eight observed a decrease in hair

loss (47.05%).

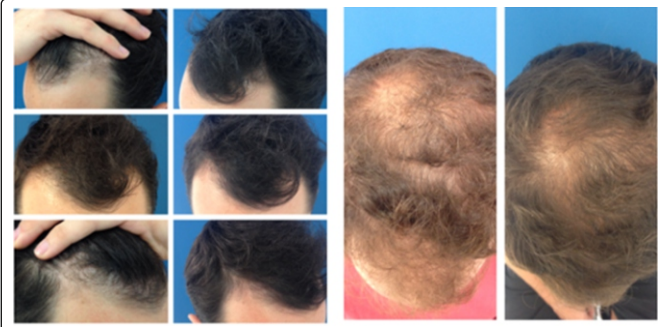

Figure 2: pre and post pictures. Left: case 1 (Day 0 top - Day 30 bottom). Right: case 2 (Day 0 left - Day 30 –right).

Table 1: Patient perception scale.

	Thickness	%	Fall	%	Density	%
Increase	12	70.58	0	0	4	23.53
No change	5	29.41	9	52.94	13	76.47
Decrease	0	0	8	47.05	0	0

For pain perception during treatment, one patient indicated a level 0 (5.88%), two patients indicated a level 2 (11.76%), seven patients indicated a level 3 (41.17%), five patients indicated a level 5 (29.41%), one patient indicated a level 6 (5.88%) and one patient indicated a level 10 (5.88%).

4. DISCUSSION:

This study evaluated changes occurring after application of the Rigenara® system in patients with AGA, or that currently suffered from significant hair loss. Said changes have been assessed in the scalp and hair bulbs using the histological study of skin biopsies and hair units; changes in hair density have been assessed using macroscopic and microscopic photographic studies; changes in hair thickness using micrometer measurements, and changes in hair loss using a Hair Loss Test.

An increase in the mean of hair thickness after application of one single therapeutic session has been objectified, which, together with a decrease in hair loss (according to the Hair Loss Test) in the same patients, suggest a certain improvement of alopecia in treated cases. It is worth noting that the levels of satisfaction most described by patients are Satisfied, Quite Satisfied or Very Satisfied with the treatment, considering its cost.

The sample size, lack of a control group, and extension of the observation period determine how to interpret the results obtained and their validity. Due to the complexity of the hair growth cycle, in order to properly evaluate the improvement in hair density, future studies should assess the trichogram as proof of analysis and perform assessments three months after treatment. Another key point is to standardize the conditions under which pictures are taken.

In general, patients' subjective assessment of the results was positive, describing an improvement mainly in thickness and hair loss, being a well-tolerated treatment concerning pain, and with no side effects. However, controlled, randomized, longer clinical trials, with a larger sample, control and placebo groups and quantifiable methods are necessary.

REFERENCES:

- Blumeyer A, Tosti A, Messenger A, Reygagne P, Del Marmol V, Spuls PI, et al. Evidence-based (S3) guideline for the treatment of androgenetic alopecia in women and in men. *J Dtsch Dermatol Ges* 2011;9:S1-57
- Talavera-Adame D, Newman D, Newman N. Conventional and novel stem cell based therapies for androgenic alopecia. *Stem Cells Cloning*. 2017 Aug 31;10:11-19
- Tsuboi R, Itami S, Inui S, Ueki R, Katsuoka K, Kurata S, et al. Guidelines for the management of androgenetic alopecia (2010) *J Dermatol*. 2012;39:113-20.
- Kaliyadan F, Nambiar A, Vijayaraghavan S. Androgenetic alopecia: an update. *Indian J Dermatol Venereol Leprol*. 2013 Sep-Oct;79(5):613-25
- Wirya CT, Wu W, Wu K. Classification of Male-pattern Hair Loss. *Int J Trichology*. 2017 Jul-Sep;9(3):95-100.
- Giaccone M, Brunetti M, Camandona M, Trovato L and Graziano A. A New Medical Device, Based on Rigenara Protocol, in the Management of Complex Wounds. *J Stem Cells Res, Rev & Rep*. 2014;1(3): 3.
- Zanzottera, F., Lavezzari, E., Trovato, L., Icardi, A. and Graziano, A. (2014) Adipose Derived Stem Cells and Growth Factors Applied on Hair Transplantation. Follow-Up of Clinical Outcome. *Journal of Cosmetics, Dermatological Sciences and Applications*, 4, 268-274. <http://dx.doi.org/10.4236/jcdsa.2014.44036>
- Elston DM, Ferringer T, Dalton S et al. A comparison of vertical versus transverse sec-

tions in the evaluation of alopecia biopsy specimens. *J AM Acad Dermatol* 2015;53:267-72

- Ashrafuzzaman Md, Yamamoto T, Shibata N et al. Potential Involvement of the Stem Cell Factor Receptor c-kit in Alopecia Areata and Androgenetic Alopecia: Histopathological, Immunohistochemical, and Semiquantitative Investigations. *JSHC* 2010;43:9-17
- Moure ERD, Romiti R, Machado MCMR et al. Primary cicatricial alopecias: a review of histopathologic findings in 38 patients from a clinical university hospital in São Paulo, Brazil. *Clinics*. 2008;63:747-52.
- Rudnicka L, Rakowska A, Kerzeja M et al. Hair shafts in trichoscopy: clues for diagnosis of hair and scalp diseases. *Dermatol Clin*. 2013;31:695708